



## Technical Service Center

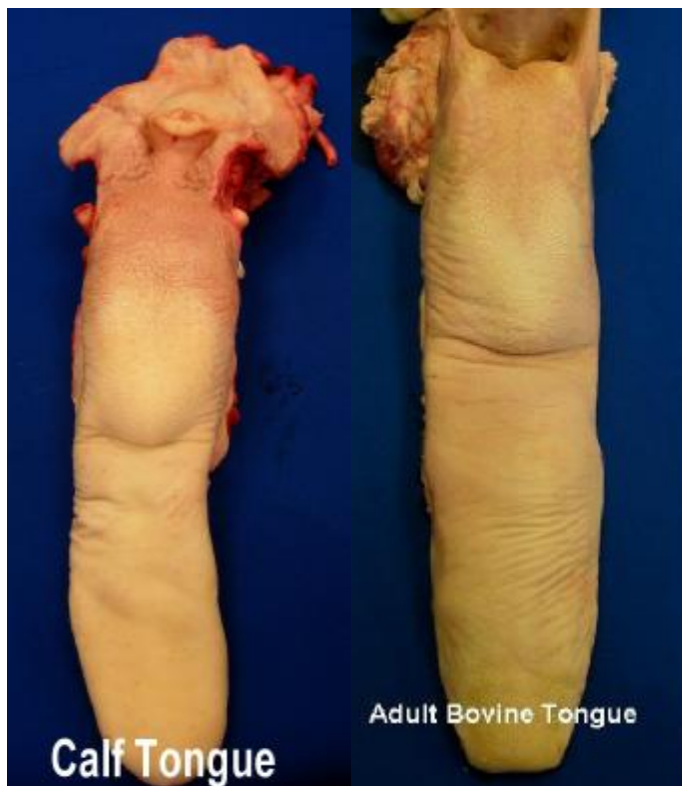Telephone 402-221-7400  
FAX 402-221-7438

TSC Postal address  
1299 Farnam Street,  
Landmark Center, Suite 300  
Omaha, Nebraska 68102

### Electronic mail

Information/Questions: [TechCenter@fsis.usda.gov](mailto:TechCenter@fsis.usda.gov)  
IKE (Interactive Knowledge Exchange): [ike@fsis.usda.gov](mailto:ike@fsis.usda.gov)

## ADDITIONAL INFORMATION & DIAGRAMS REGARDING THE REMOVAL OF TONSILS IN CATTLE



These pictures identify the first step in the removal process. Typical head dressing procedures result in tongues, similar to these, being presented with associated tissues including lymph nodes, fatty tissues, salivary glands, and tonsils (i.e. palatine and lingual tonsils). Since these tonsils are SRM, they are to be removed.

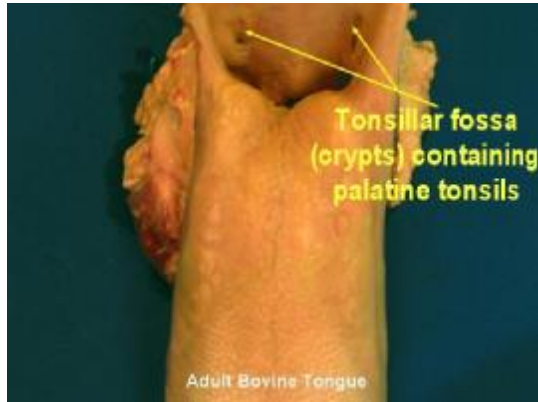

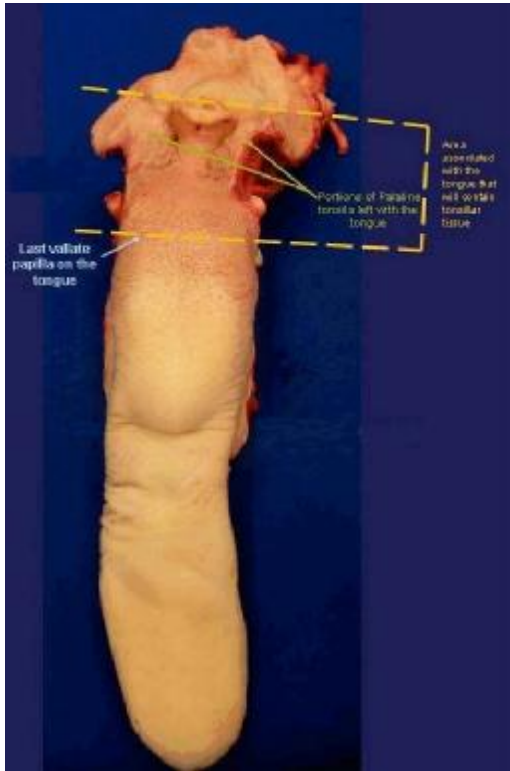
Photo demonstrating the location of the palatine fossa (crypts) which contain the palatine tonsils.

These tonsils are SRM and are to be removed.

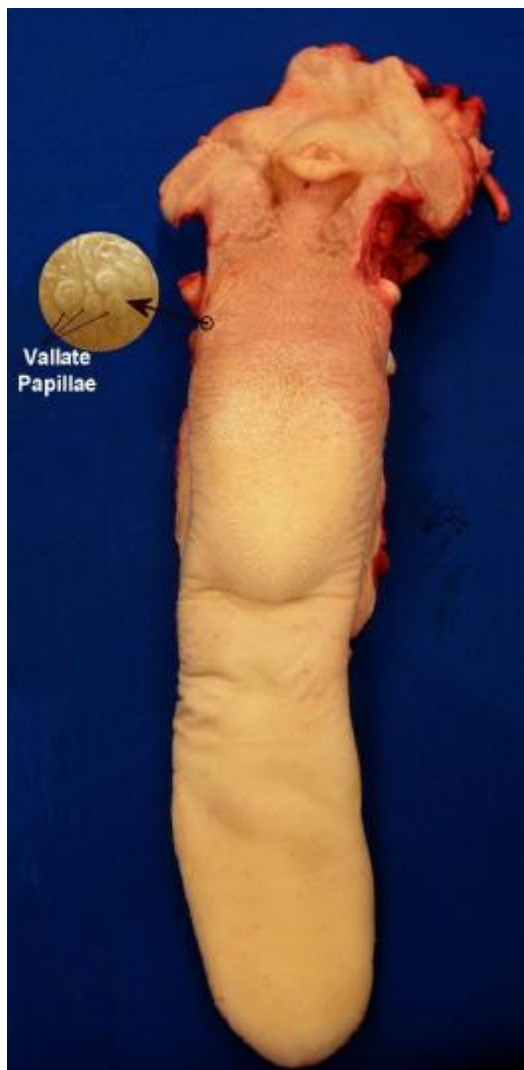

Photo identifying the vallate papillae.

Isolation of the edible portion of the tongue from the lingual tonsil will be accomplished by making a transverse cut just behind the last (most rear) vallate papilla.



This photo further identifies the specific portion of the tongue containing both sets of tonsils (i.e. lingual and palatine) which are SRM.

Removal of the edible portion of the tongue is accomplished by making a transverse cut (yellow line) just behind the last vallate papilla.

